

## Ovarian Dysgerminoma During Pregnancy: Case Report

Alan Francis Miranda Flores<sup>1\*</sup> | Roxana Risco Neyra<sup>2</sup>

\*Correspondence: Alan Francis Miranda Flores

Address: <sup>1</sup>Obstetrician Gynecologist, Gynecologist Oncologist, Department of Gynecology, National Maternal Perinatal Institute, Lima, Peru; <sup>2</sup>Radiation Oncologist, Tumbes Regional Health Directorate, Tumbes, Peru

e-mail ✉: [alanmiranda04@hotmail.com](mailto:alanmiranda04@hotmail.com)

Received: 06 June 2022; Accepted: 17 June 2022

Copyright: © 2022 Miranda Flores AF. This is an open-access article distributed under the terms of the Creative Commons Attribution License, which permits unrestricted use, distribution, and reproduction in any medium, provided that the original work is properly cited.

### ABSTRACT

Ovarian dysgerminoma during pregnancy is rare, with an incidence of approximately 0.2 to 1 per 1,000,000 pregnancies, generally affecting adolescents and young adults under 30 years of age. Detection during pregnancy is difficult. Most are diagnosed early. Proper management of these neoplasms to improve both maternal and neonatal outcomes remain a challenge. We present the case of a 23-year-old patient, with 38 weeks of gestation, mental retardation, who goes to the emergency room due to uterine contractions.

**Keywords:** Ovarian Dysgerminoma, Pregnancy, Malignant Germ Cell Tumor

### Introduction

The incidence of ovarian cancer is 2.8 to 11 per 100,000 pregnancies, where 18 to 26% of cases are malignant germ cell tumors. The most frequent subtype is dysgerminoma (38.2%) (Sas *et al.*, 2021; Zhang *et al.*, 2020; Chen *et al.*, 2018; Kodama *et al.*, 2014).

The incidence of ovarian dysgerminoma is approximately 0.2 to 1 per 1,000,000 pregnancies, they are rare (Sas *et al.*, 2021; Chen *et al.*, 2018). They predominantly affect adolescents and young adults (Sas *et al.*, 2021). Diagnosis is generally difficult (Douaguibe *et al.*, 2021). It is usually unilateral and diagnosed at an early stage (Zhang *et al.*, 2020; Douaguibe *et al.*, 2021).

Early prenatal diagnosis and proper management of these neoplasms to improve both maternal and neonatal outcomes continues to be a challenge faced by the gynecologist oncologist (Zhang *et al.*, 2020). Due to its infrequency, there are few recommendations regarding its management in pregnancy (Chen *et al.*, 2018). Dysgerminomas are very sensitive to chemotherapy, which has improved their prognosis.

The case of a patient with ovarian dysgerminoma during pregnancy with mental retardation is reported.

## Case Report

23-year-old patient with mild mental retardation, second pregnancy, no family history, history of previous cesarean section 5 years ago, with 7 prenatal controls. blood group O Rh+, non-reactive serological tests (HIV, RPR), with a pregnancy of 38 weeks by date of last menstrual period. She has an ultrasound result from the fetal medicine unit of our institution on 3/16/2022 that concludes a single active gestation of 33 weeks + 2 days, weight 2066g, high grade I anterior placenta, amniotic fluid index 16cm, normal doppler, evidence abdominal mass left lateral to the uterus, hypoechoic, 19x9x15 cm, volume 1429cc, origin not feasible to specify. She goes to the emergency room due to uterine contractions. On physical examination, he had blood pressure of 126/76 mmHg, heart rate of 85 beats per minute, respiratory rate of 18 per minute, temperature of 36.70, oxygen saturation of 98%, uterine height of 32 cm, fetal heartbeat at 138 beats per minute, right podalic longitudinal, sporadic uterine dynamics, fetal movements present. Vaginal examination shows no cervical changes, presentation height -4, gynecoid pelvis, no loss of amniotic fluid, no evidence of vaginal bleeding.

Laboratory tests reported a hemoglobin of 11.8 gr/dl, leukocytes of 7,300 cells/mm<sup>3</sup>, coagulation profile within normal parameters, glucose of 80 mg/dl, urea of 27 mg/dl, creatinine of 0.60 mg/dl, non-reactive Covid-19 antigen, negative urine test (Table 1). A non-stress test was requested with a score of 9/10, active-reactive, with the presence of uterine dynamics, 1 contraction every 10 minutes. Therefore, it was decided to schedule an emergency cesarean section with gestation diagnoses of 38ss by date of last period, labor prodromes, previous cesarean section 1 time, fetus in podalic, abdominal-pelvic tumor, rule out uterine myoma.

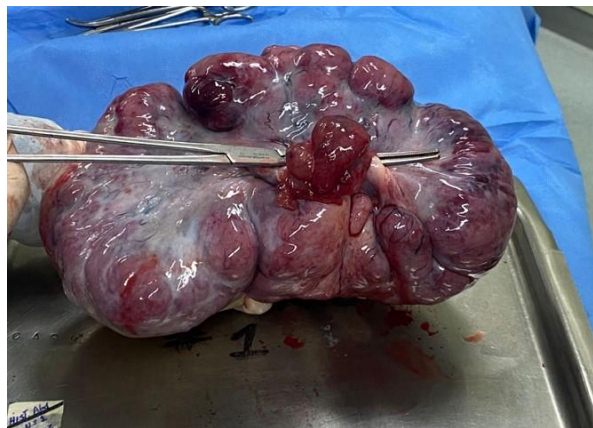During cesarean section, 300cc sallow ascitic fluid was evidenced, she gave birth to a newborn, weighing 3100 g, height 49.3 cm, Apgar score of 8 at minute and 9 at 5 minutes, clear amniotic fluid. She presented uterine hypotonia, which did not subside with medical management, so uterine packing was performed according to the B-Lynch technique. There is evidence of a multilobular left adnexal tumor, with a cerebroid appearance, irregular surface, semi-solid consistency, 25x15 cm, uterine tube adhered to the tumor, for which it was decided to perform a left adnexectomy (Fig. 1-2). During surgery there was no pathologist for frozen biopsy. No signs of carcinomatosis were evident. The placenta, ascitic fluid and tumor were sent to pathology.

During her days of hospitalization, the patient evolved favorably, her control hemoglobin was

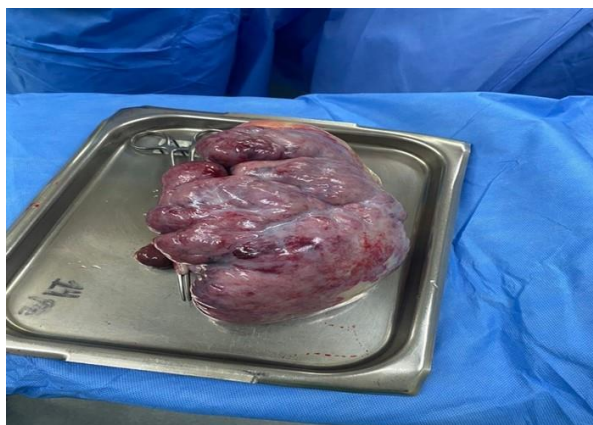10.5 gr/dl. A total abdominal ultrasound was performed, which concluded moderate hepatic steatosis, without adenopathies. The result of the macroscopic pathology was a tumor of 22x14x10 cm, 1870 gr, smooth external surface, lobulated appearance, light brown, attached to the uterine tube, light brown area on cut, with areas of necrosis and degenerative areas; concludes dysgerminoma, intact and compromised capsule, present necrosis, mitosis 20/10 HPF, peritubal tissue compromiso (Fig. 3). The ascitic fluid study does not show malignant neoplasm cells. The placenta with normal characteristics. She was evaluated by the gynecologist oncologist, where it was decided to refer her to the National Institute of Neoplastic Diseases for treatment with chemotherapy.

**Table 1:** Lab results.

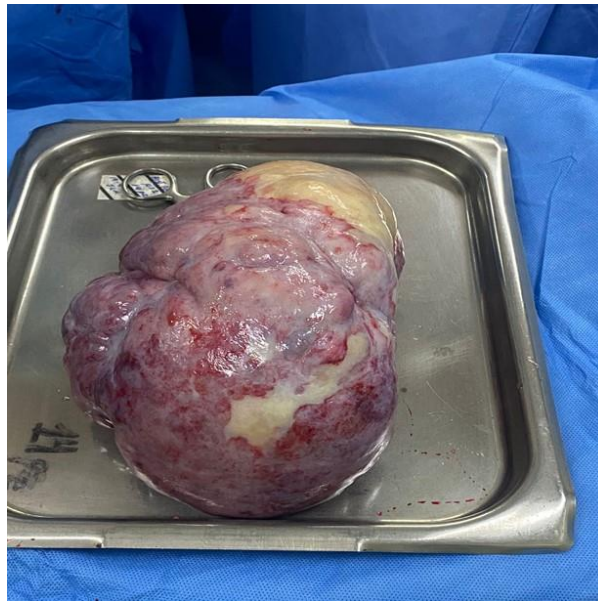
Hemoglobin	11,8gr/dl
Leukocytes	7300 cellsxmm <sup>3</sup>
Glucose	80 mg/dl
Urea	27 mg/dl
Creatinine	0,60 mg/dl
Antigen-Covid-19	non reactive
Urine test	negative



**Figure 1:** Left ovarian solid tumor (Dysgerminoma).



**Figure 2:** Ovarian mass with a cerebroid and lobulated appearance.



**Figure 3:** Ovarian mass with a smooth, light brown surface.

## Discussion

The malignant germ cell tumor represents less than 5% of all ovarian cancers, it is uncommon, with little known behavior during pregnancy, with dysgerminoma being the most frequent subtype (38.2%) (Sas *et al.*, 2021; Zhang *et al.*, 2020; Chen *et al.*, 2018; Kodama *et al.*, 2014; Gauza1 *et al.*, 2010). The incidence of dysgerminoma is approximately 0.2 to 1 per 1,000,000 pregnancies (Sas *et al.*, 2021; Chen *et al.*, 2018). Kodama, *et al.* (2014) carried out a systematic review of malignant germ cell tumor associated with pregnancy, identifying 102 cases, the most frequent histological subtype being dysgerminoma (38.2%), followed by yolk sac tumor (30.4%).

Ovarian dysgerminoma generally occurs in reproductive age, in those under 30 years of age (Sánchez *et al.*, 2013). Chen, *et al.* (2018) reported a mean age of 24+-4.4 years (range 17-33 years), with 86.4 % under 30 years. The reported case was 23 years old.

Chen, *et al.* (2018) in their series found that 50% (11 cases) were their first pregnancy, 7 were in their second pregnancy and 4 were pregnant for the third time. The reported case was her second pregnancy.

Most pregnant women with dysgerminoma usually present nonspecific symptoms, including the most frequent abdominal pain (35.3%), abdominal distension (19.6%), growing mass (19.6%), multiple symptoms (18.6%) and asymptomatic (21.6%) (Sas *et al.*, 2021; Zhang *et al.*, 2020). Kodama, *et al.* (2014) reported that the most frequent symptom was abdominal pain (35.3%). Chen. *et al.* (2018) reported that more than half of the cases were asymptomatic (52.4%), abdominal pain (28.5%), abdominal distention

(9.5%) and obstructed labor (9.5%). In our case report, she was asymptomatic during her pregnancy, she went to the emergency room due to uterine contractions.

Detection during pregnancy is difficult, the growing uterus interferes with adequate abdominal or pelvic examination. Thanks to the use of ultrasound in prenatal care, ovarian dysgerminomas are detected more frequently, but there are no characteristics of particular images by ultrasonography (Chen *et al.*, 2018). A review of the literature reports that it is not uncommon to misdiagnose a dysgerminoma by ultrasound and diagnose uterine fibroids instead.<sup>8</sup> In our case, it was thought to be a giant uterine fibroma. Magnetic resonance imaging can detect the origin of an ovarian tumor with a sensitivity of around 98%. However, there have been reports of mistaking a malignant ovarian tumor for a pedunculated uterine fibroid with areas of cystic degeneration (Youssef *et al.*, 2021).

Tumor markers such as alpha-fetoprotein, lactate dehydrogenase, and human chorionic gonadotropin can help in diagnosis, however values should be interpreted with caution during pregnancy, as there are wide variations in results and poor specificity due to physiological changes in pregnancy (Chen *et al.*, 2018).

Dysgerminomas are usually unilateral in pregnancy in approximately 95%, only 5% to 20% are bilateral (Zhang *et al.*, 2020). Chen, *et al.* (2018) reported that most tumors were unilateral (95%), only one case was bilateral (5%). Some authors reported that bilateral dysgerminomas were found in 12-20% of pregnancy cases (Chen *et al.*, 2018). In our case it was unilateral.

In general, dysgerminomas are well encapsulated, solid in consistency, with a diameter range of 8 to 15 cm (Zhang *et al.*, 2020). In the study by Chen (Chen *et al.*, 2018), the mean diameter of dysgerminomas was 14.7±7.8 cm (range 4 -30 cm), with 20% measuring ≥ 20 cm and 80% less than 20 cm. In our case the tumor measured 22cm.

Dysgerminomas can affect conception and during pregnancy can cause maternal-fetal compromise (Sas *et al.*, 2021; Chen *et al.*, 2018). An increased risk of torsion, incarceration, rupture and hemorrhage may occur during pregnancy and vaginal delivery (Sas *et al.*, 2021). Chen, *et al.* (2018) reported 2 cases of tumor torsion that occurred in the puerperium and second trimester, 2 cases of tumor incarceration due to obstructed labor and 2 cases of tumor rupture diagnosed during surgical exploration. Kodama, *et al.* (2014) in their systematic review of malignant germ cell tumor associated with pregnancy reported obstructed labor, tumor rupture and torsion in 2.9%, 8.8% and 1.0% respectively. Fetal death has been reported to occur in 25% of cases.<sup>1</sup> In our case, there was no maternal-fetal compromise. Bakri, *et al.* (2000) reported that the association of dysgerminoma and pregnancy did

not negatively affect tumor prognosis or fetal outcome (Lee *et al.*, 2011).

Most dysgerminomas during pregnancy are diagnosed in the early stage, with 75% being stage I, the contralateral ovary being involved in 10 to 15% of cases (Sas *et al.*, 2021). In the study by Chen<sup>3</sup> he reported that 77.3% of cases were clinical stage I, while clinical stage II, III and IV were 4.5%, 9.1% and 9.1% respectively. In our case, it was clinical stage IIA due to involvement of the tube, according to FIGO 2021.

The management of ovarian cancer in pregnancy is complicated, decisions in each case must be individual, taking into account age, clinical stage, gestational age, parity, current desire for pregnancy and future fertility (Sas *et al.*, 2021; Chen *et al.*, 2018). Almost all malignant germ cell tumors can be treated by conservative surgery, without affecting survival, since they are sensitive to chemotherapy (Castillo *et al.*, 2017). The group of women of childbearing age is the most affected, treatment should consider the preservation of fertility (Sánchez *et al.*, 2013).

There is evidence showing that fertility-sparing surgery for clinical stage IA ovarian dysgerminoma is safe with a 10-year survival of 91% (Chen *et al.*, 2018). These tumors are highly chemosensitive, with a survival rate greater than 95% for tumors confined to the ovary and 60 to 80% for advanced stage tumors (Kodama *et al.*, 2014). In our case, the patient was referred to another hospital for chemotherapy treatment.

## Conclusion

Ovarian dysgerminoma in pregnancy generally occurs in young women, is mostly diagnosed at an early stage and its detection during pregnancy is difficult. Its management in pregnancy is complicated, so each case must be discussed individually. His prognosis is excellent.

**Conflicts of Interest:** The author expresses no conflict of interest.

## References

Bakri Y, Ezzat A, Akhtar, Dohami, Zahrani. Malignant germ cell tumors of the ovary. Pregnancy considerations. *Eur J Obstet Gynecol Reprod Biol* 2000; 90: 87-91.

Castillo L, Delgado A, Arteaga G. Cáncer de ovario durante el embarazo: experiencia institucional y revisión de la bibliografía. *Ginecol Obstet Mex* 2017; 85: 224-233.

Chen Y, Luo Y, Han C, Tian W, Yang W, Wang Y, Xue F. Ovarian dysgerminoma in pregnancy: A case report and literature review. *Cancer Biol Ther* 2018; 19: 649-658.

Douaguibe B, M'Bortche BK, Keteve TA, Bassowa A, Ajavon D, Dare T, Baramna-Bagou F, Migbegna KA, Aboubakari AS, Akpadza K. Ovarian Dysgerminoma Associated with Pregnancy: A Case Report from the Sylvanus Olympio University Hospital Center. *Open J Obstet Gynecol* 2021; 11: 830-835.

Gauza1 J, García R, Silva J, Blind P, Da Rocha D, Quintana S. Diagnosis of ovarian dysgerminoma during pregnancy. *Rev Assoc Med Bras* 2010; 56: 517-519.

Kodama M, Grubbs B, Blake E, Cahoon S, Murakami R, Kimura Matsuo K. Feto-maternal outcomes of pregnancy complicated by ovarian malignant germ cell tumor: a systematic review of literatura. *Eur J Obstet Gynecol Reprod Biol* 2014; 181: 145-156.

Lee Y, Yoo Y, Lee G, Park D. Ovarian dysgerminoma associated with pregnancy. *Korean Journal of Obstetrics and Gynecology* 2011; 54: 218-222.

Sánchez Y, Urdaneta J, Villalobos I, Torres N, Carrero L. Cáncer de ovario en el embarazo. Reporte de un caso. *Rev Chil Obstet Ginecol* 2013; 78(5): 371-378.

Sas I, Serban D, Tomescu L, Nicolae N. Ovarian dysgerminoma in pregnancy: A case report. *Medicine* 2021; 100: e25364.

Youssef R, Ahmedb S, Alhyassat S, Badr S, Sabrya A, Kohla S. Ovarian Dysgerminoma in Pregnant Women with Viable Fetus: A Rare Case Report. *Case Rep Oncol* 2021; 14:141-146.

Zhang X, Zhai L, Huang D, Jiang Z, Yu T, Liu S, Cui M. Pregnancy with giant ovarian dysgerminoma. A case report and literature review. *Medicine* 2020; 99: e21214.